



Shoulder & Arm

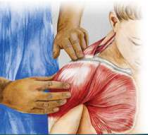2

Trail Guide
to the Body

Introduction

Reflect on your own experiences...

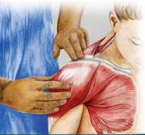- Do you have any hobbies that heavily involve your shoulder?
- Which ones and have you ever injured them before?



Introduction (cont.)

Observe your own body...

- Place your left hand on top of your left shoulder.
- Can you feel the bones with the various bump and knobs?
- Now notice where there is muscle tissue.
- Where is it thicker versus thinner or nonexistent?



Introduction (cont.)

Get moving...

- Reach your right hand up and scratch the top of your head.
- How many joints do you think are involved in creating that action?
- Can you name any muscles that contract during the complex action of reaching up to the top of your head?



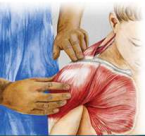Surface Anatomy, Bones, and Bony Landmarks of the Shoulder and Arm

Learning Objectives

Observe and confidently explore the surface anatomy including skin and fascial structures of the shoulder and arm.

Palpate the bones and bony landmarks of the shoulder and arm and explore the connections between them and soft tissue.

Palpate the shoulder and arm landmarks that identify the location of underlying nerves, blood vessels, and lymph nodes to be cautious of when practicing manual therapy.



Surface Anatomy, Bones, and Bony Landmarks of the Shoulder and Arm (cont.)

Learning Objectives

Describe the relationships between the topographical contours and underlying musculoskeletal structures, as well as the texture, thickness, and mobility of the skin and fascial structures in the shoulder and arm.

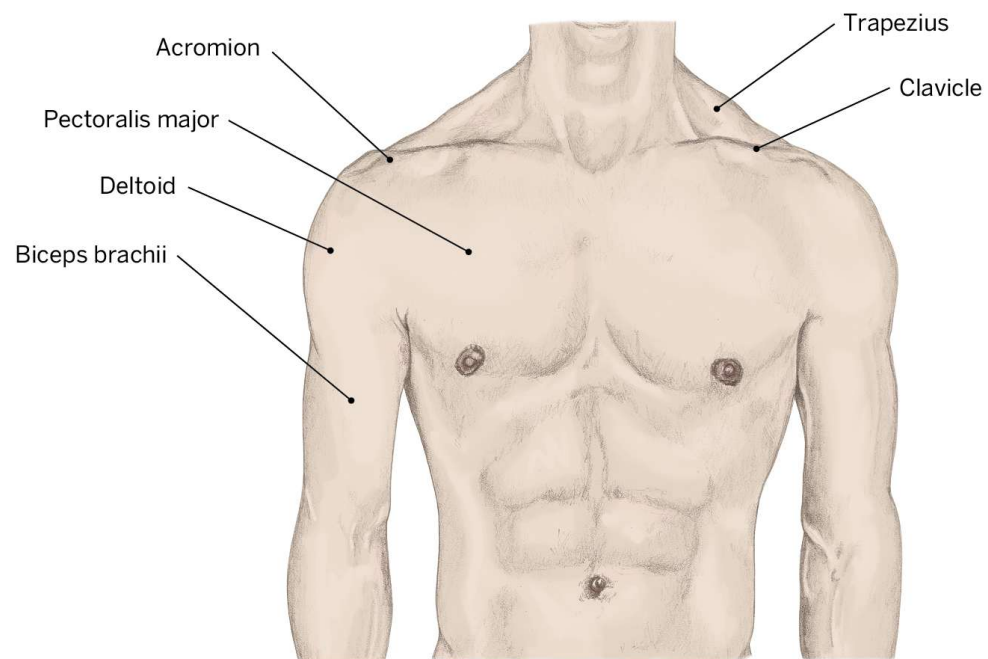
Name and locate the bones, bony landmarks, and joints for the shoulder and arm and describe the connections between them and the soft tissues of the shoulder and arm.

Name and locate major joint structures of the shoulder and arm, including ligaments and bursae that are common sites of pain and injury in the region.



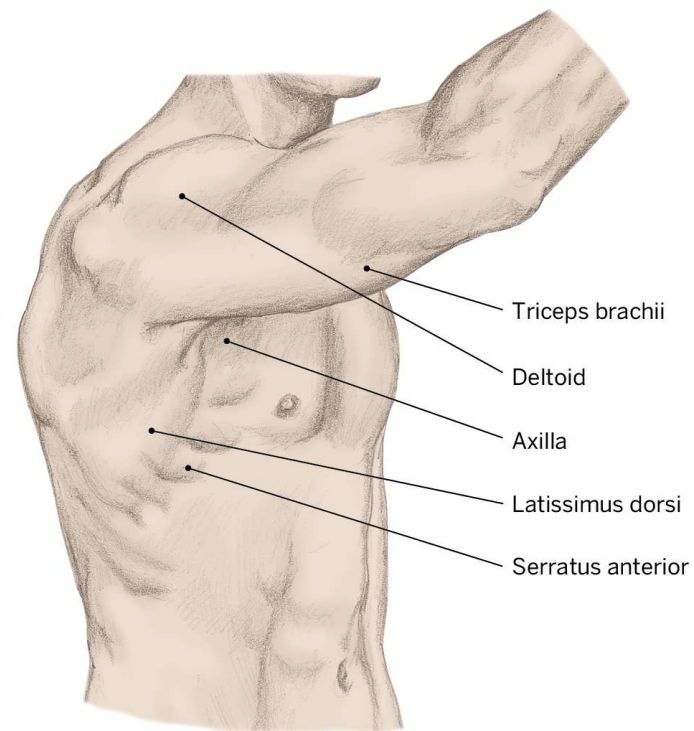
Surface Features Visible on the Shoulder and Arm

Anterior view



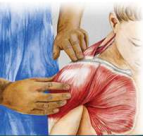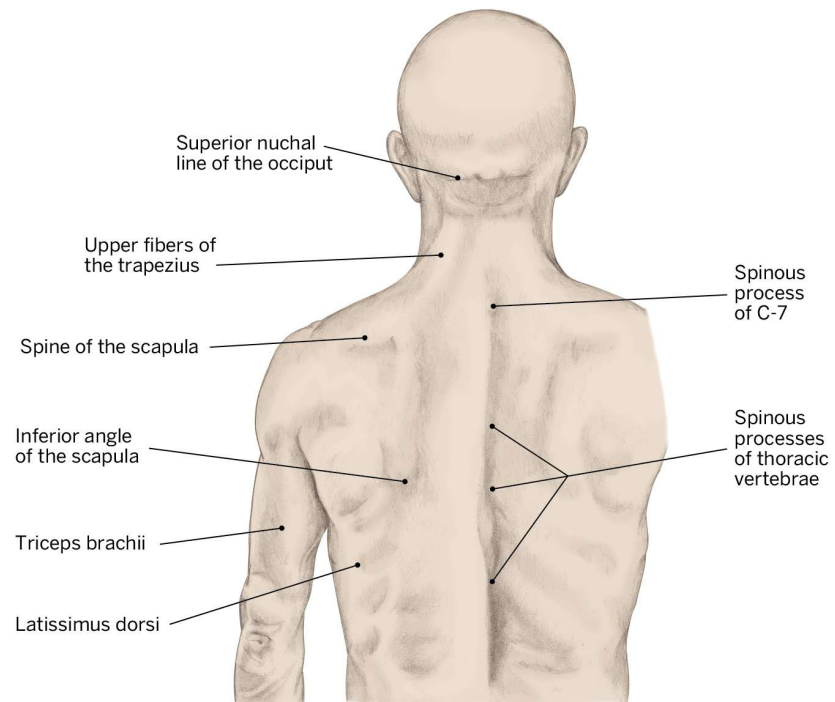
Surface Features Visible on the Shoulder and Arm

Anterior/lateral view



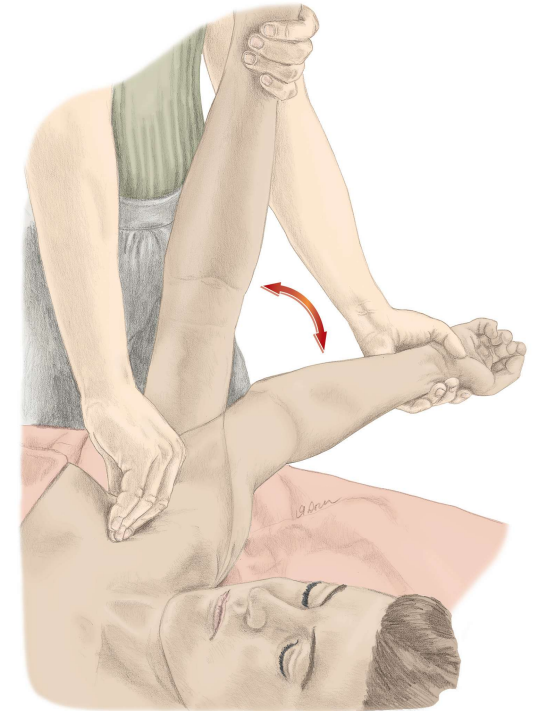
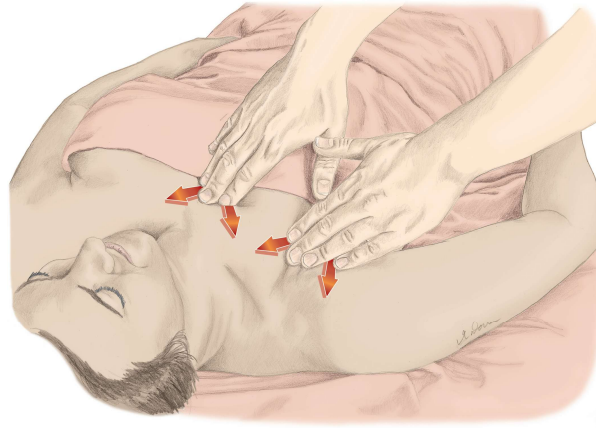
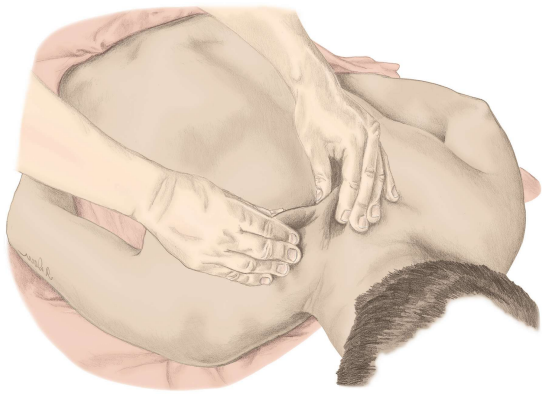Surface Features Visible on the Shoulder and Arm

Posterior view



Shoulder & Arm

Explore and Palpate!



Trail Guide to the Body (p. 43)